

# MDR-TB patient TB relapse after COVID -19

Dr Arusyak Melikyan  
Monitoring and Evaluation Specialist,  
NTP Armenia  
15.10.2021

# Patient's history

- ▶ M. G., 63-year-old male
- ▶ TB since 2016
- ▶ Diagnosis: infiltrative TB, left lung upper lobe in destruction phase, dissemination, MDR-TB, chronic hepatitis C.
- ▶ DST results: resistance to R,H,E,Z,S, susceptibility to Ami, Ofx;
- ▶ 14.04.2016–30.06.2016 – treatment with Cm,Cs,Mfx,Pto,Pas, Z
- ▶ Treatment adjustment: Dlm, Imp+ Amx /Clv,Cm, Lfx,Cfz
- ▶ 08.08.2016r Cs and Dlm discontinued, started on Bdq


# Treatment management

## Adverse reactions

QTcF interval prolongation, hepatotoxicity, ototoxicity, treatment or medication was discontinued repeatedly (Bdq or Cfz)

- 21.12.2016 – Cm discontinued, started on Cs
- 14.04.2017 r, Bdq and Cfz permanently discontinued
- Hepatitis C treatment (27.07.2017–16.10.2017 SOF+ DCV), G –x HCV SVR 12 \_neg\_ cure
- TB treatment continued with the following regimen:  
Imp+ Amx/Clv,Cs,Lfx, Pto till 09.07.2018
- Treatment outcome – cure

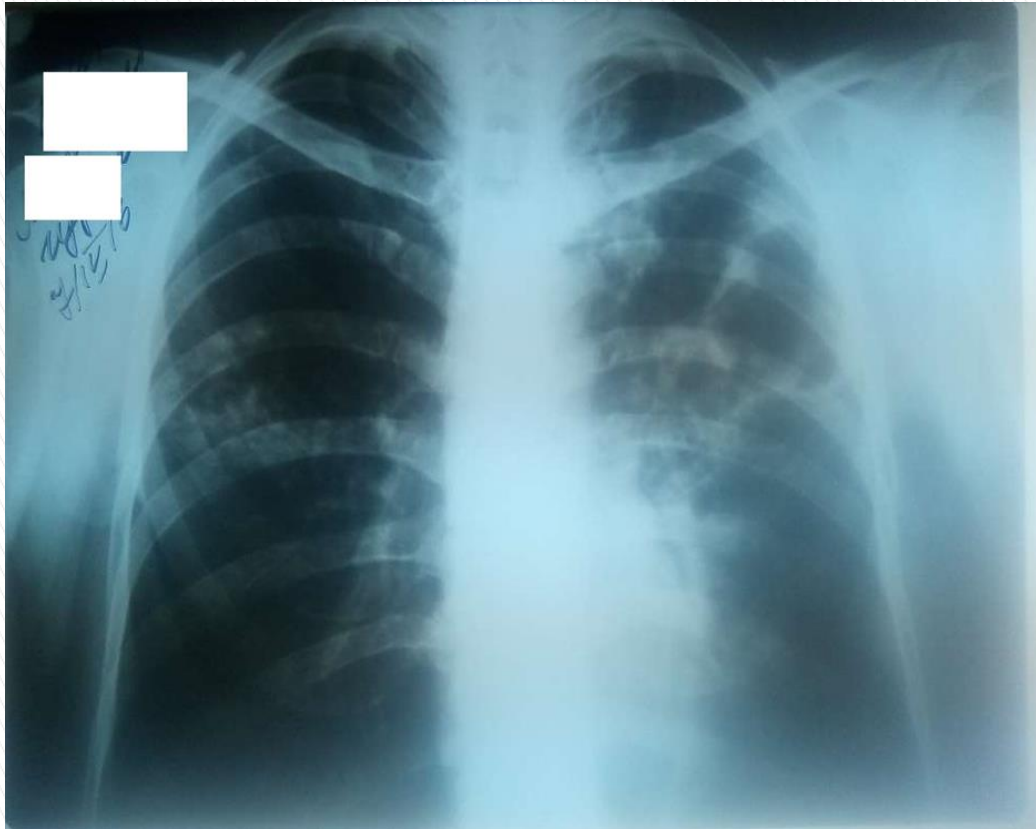
# Mycobacteriology test results in the course of treatment

- ▶ 08.04.2016 SS pos., SC pos. DST results: resistant to HRZE, Sensitive to Am ; Ofx
  - ▶ 14 negative cultures (last positive result reported on 06.09.2016)
  - ▶ Radiology results – positive trend
  - ▶ In august 2018 – PAS discontinued
  - ▶ 11.01.2019 – regular evaluation (x-ray, sputum), no exacerbation of the TB process reported
- 

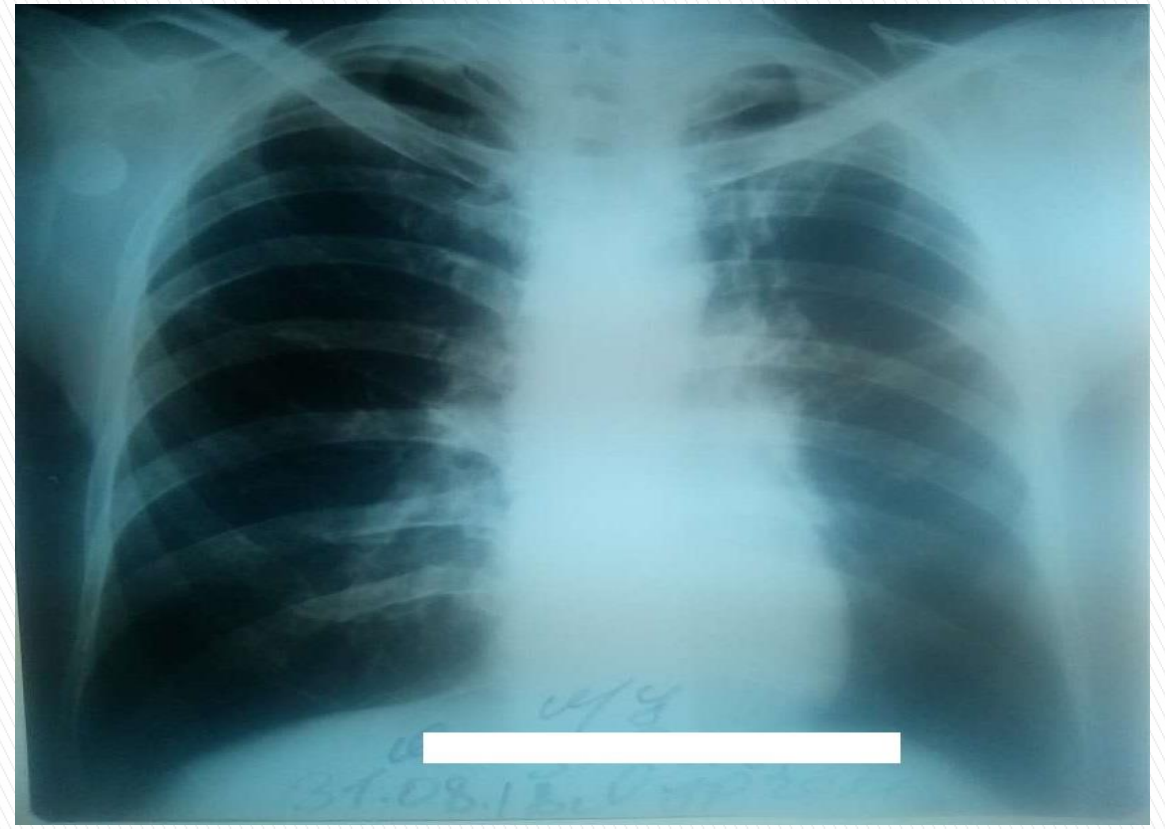
# COVID 19

- ▶ October 2020 – contracted Covid, mild condition
- ▶ Home treatment, dexamethasone was not indicated
- ▶ 26.11.2020 – hospitalization at the TB clinic – pulmonary infiltrative TB in dissemination phase. Positive bacteriology results+MDR, relapse
- ▶ DST results – resistance to H, R, E, Z, Ami, susceptibility to FLQ, Ami
- ▶ 28.11.2020 started on Bdq, Dlm, Lfx, Cfz, Cs
- ▶ 29.12.2020 sleeping disorder, Cs replaced with Lzd
- ▶ Prolongation of QTcF interval (19.03.2021 QTcF= 485
- ▶ 02.04.2021 QTcF = 490;09.04.21 QTcF = 470;
- ▶ 13.04.2021 QTcF= 485:

# Radiology examination

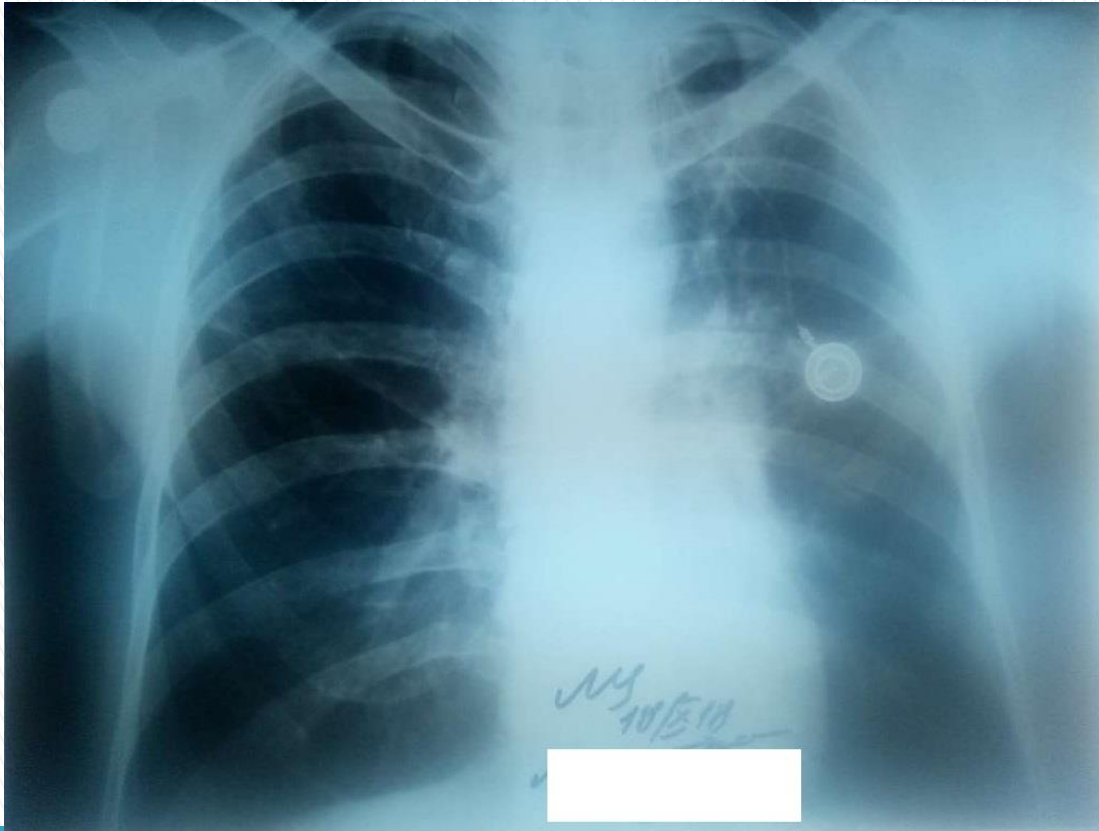


04.2016 /

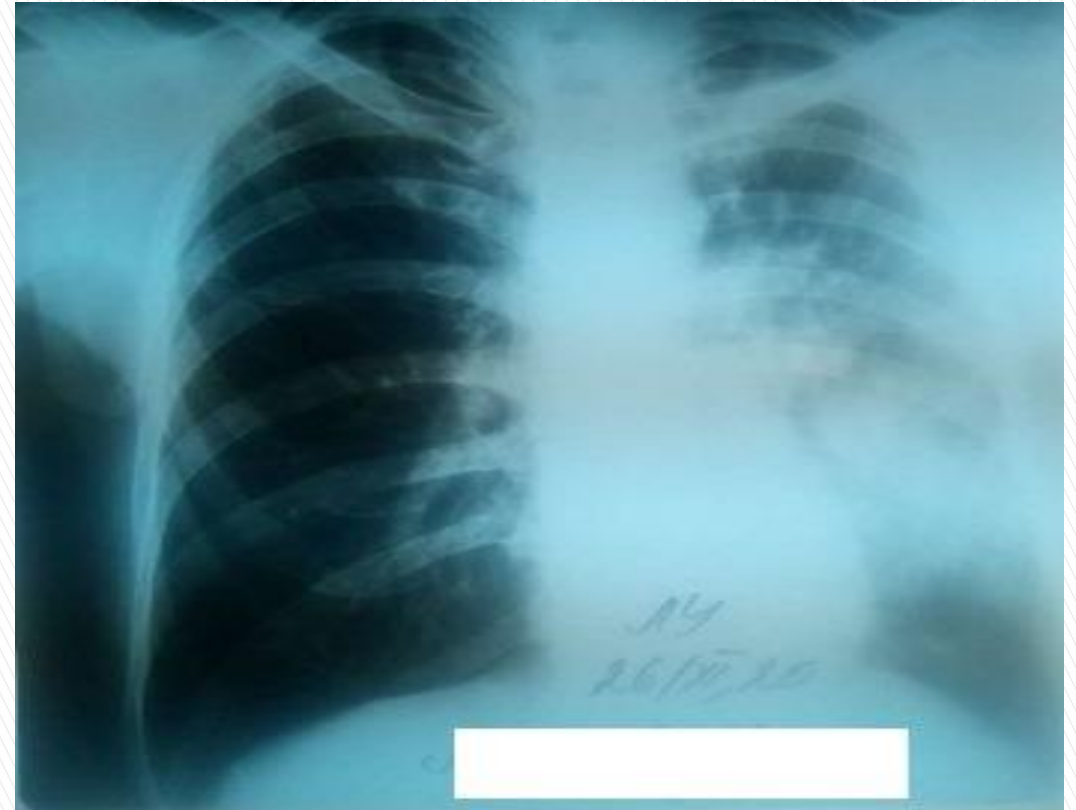


08.2018

# Radiology examination

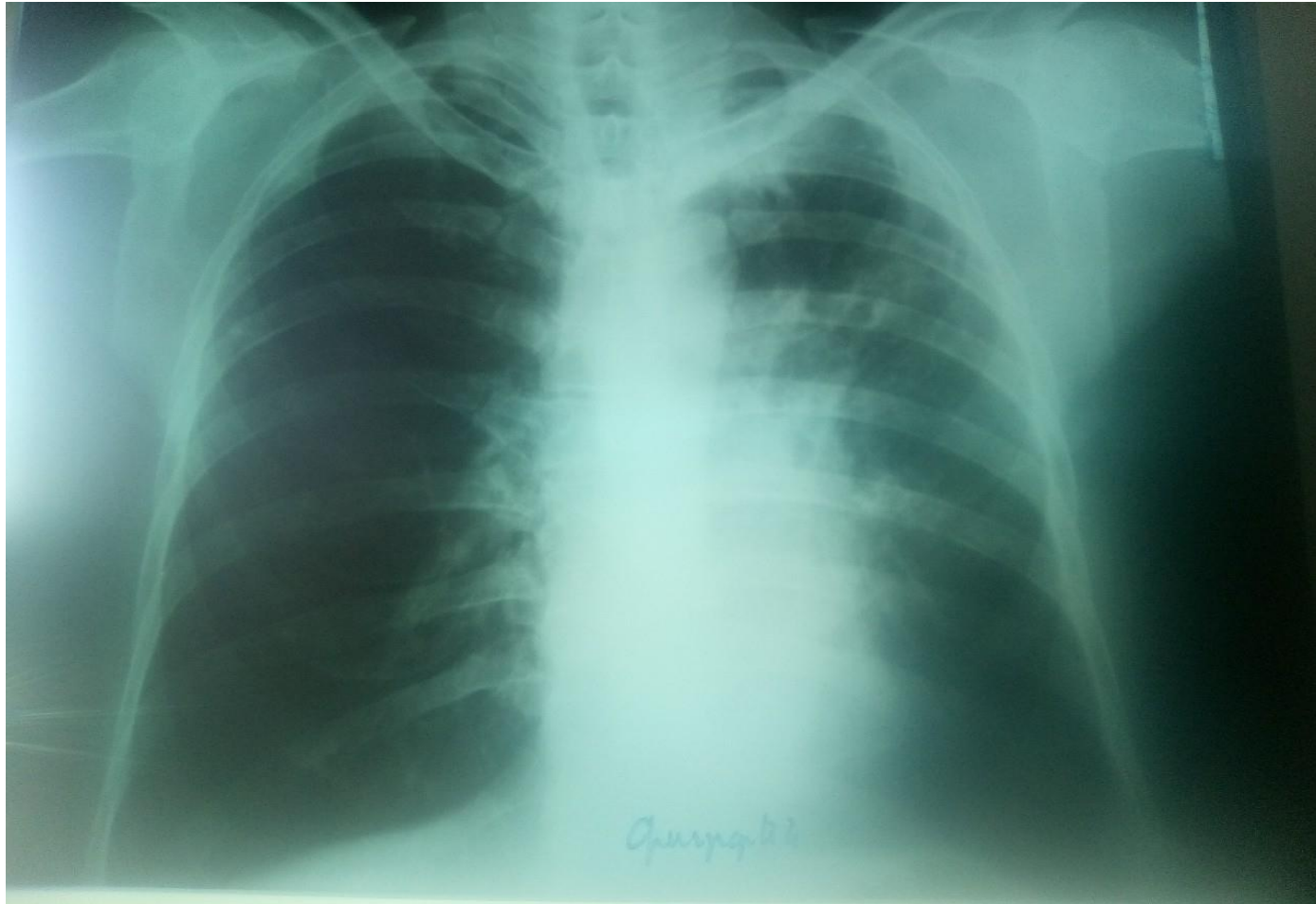


10.2018



11.2020

# Radiology examination on 09.2021





# Adverse reactions

## Adverse reactions

Prolongation of QTcF interval up to 490m/sec

- ▶ Treatment is temporarily discontinued while looking for the cause
- ▶ Patient is discharged from the inpatient clinic on 05.03.2021
- ▶ Did not receive medication for about a month
- ▶ Treatment continued at the local TB unit

## Changes in treatment

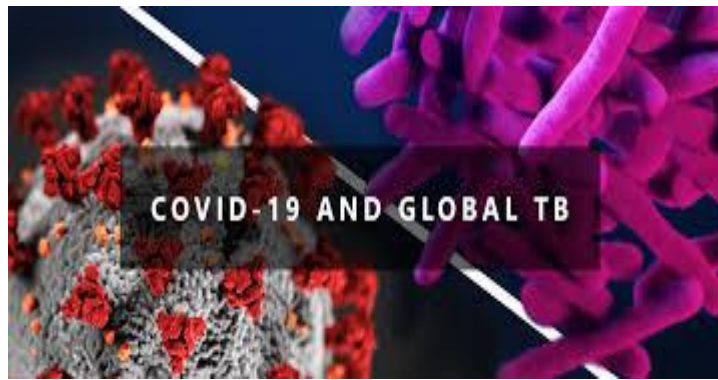- ▶ Treatment discontinued from 03.03.2021 to 20.04.2021
- ▶ 20.04.2021 started on DIm+ Lzd
- ▶ 26.04.2021 QTcF = 406; + Bdq
- ▶ 01.05.2021 QTcF = 413; +Cfz+Lfx
- ▶ Receives Bdq-Lzd-Lfx-Cfz- DIm
  
- ▶ Current treatment is well tolerated
- ▶ 20.09.21 QTcF=390; ALT=21, AST= 33,0

# Changes in treatment

- ▶ Treatment discontinued from 03.03.2021 to 20.04.2021
- ▶ 20.04.2021 started on DIm+ Lzd
- ▶ 26.04.2021 QTcF = 406; + Bdq
- ▶ 01.05.2021 QTcF = 413; +Cfz+Lfx
- ▶ Receives Bdq-Lzd-Lfx-Cfz- DIm
  
- ▶ Current treatment is well tolerated, patient is adherent to treatment
- ▶ 20.09.21 QTcF=390; ALT=21, AST= 33,0



We are strong-willed, we are a team, we will overcome Covid/TB



Thank you!